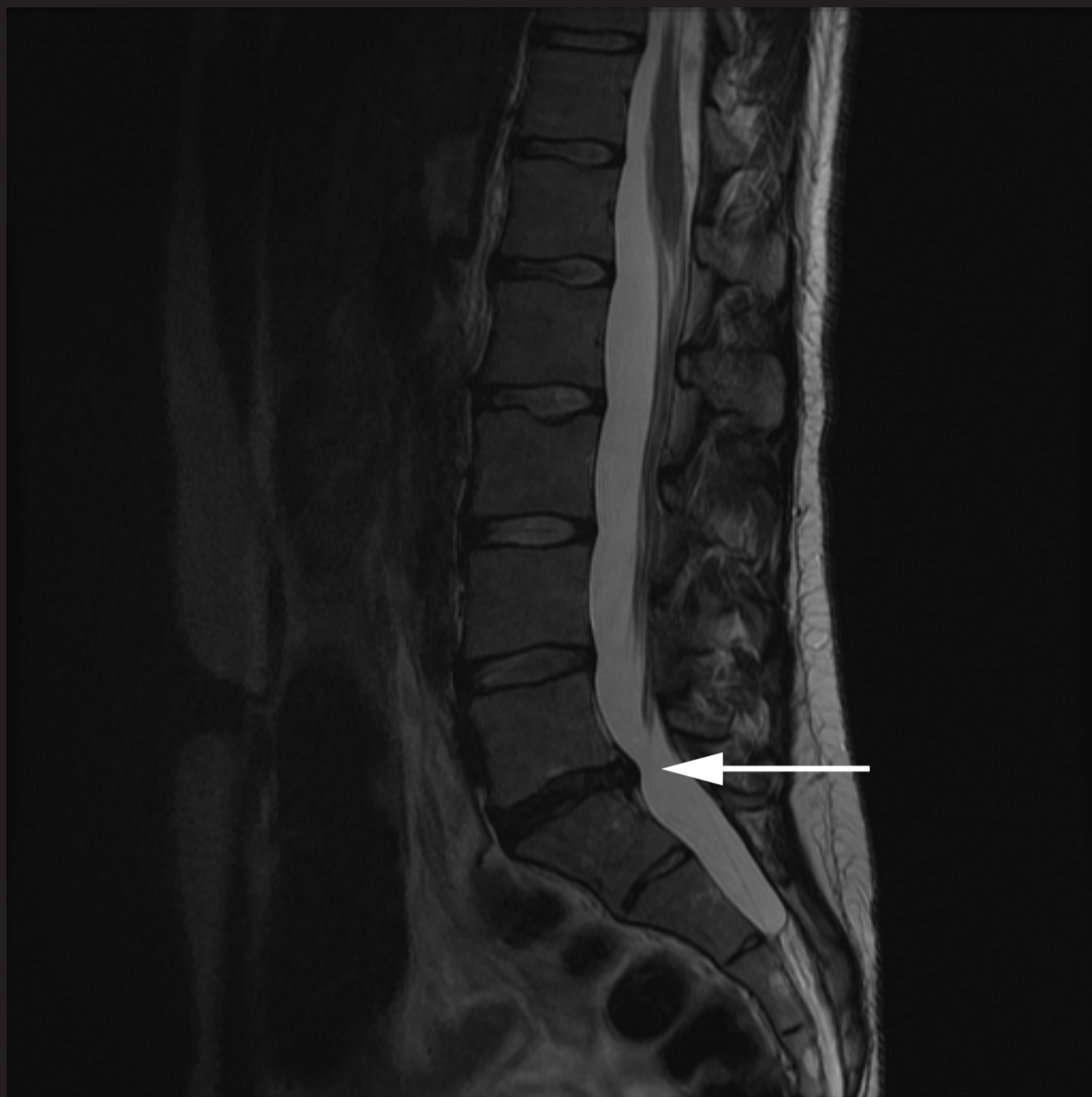


L5/S1 disc protrusion into spinal canal shown on MR.
Sagittal (left) and axial (right) projections.

Sagittal view



Axial view

